

SMP Cardiology and Cardiovascular Medicine

Unexplained Pulmonary Hypertension or Diastolic Heart Failure

Ostroumov Evgeniy N^{*}*Nuclear Medicine Consultant NV Sklifosovsky Research Institute for Emergency Medicine, Russia*

Publication Dates

Received date: February 28, 2024

Accepted date: March 28, 2024

Published date: March 31, 2024

^{*}Corresponding Author

Ostroumov Evgeniy N, Nuclear Medicine Consultant NV Sklifosovsky Research Institute for Emergency Medicine, Russia, E-mail: oenmagadan@yandex.ru

Citation

Ostroumov Evgeniy N (2024) Unexplained Pulmonary Hypertension or Diastolic Heart Failure, SMP Cardiol Cardiovasc Med, 1: 1-8

Copyright link et al. This article is distributed under the terms of the Creative Commons Attribution License, which permits unrestricted use and redistribution provided that the original author and source are credited.

Abstract

With the advent of the era of multimodal research in cardiology, new opportunities have arisen in making a competent diagnosis. At the same time, the use of multimodal methods requires collective decisions or special knowledge not only of radiologists, but also of attending physicians. You are presented with a case where the use of such methods to explain pulmonary hypertension in a patient with coronary artery disease with normal LVEF and manifestations of heart failure still did not lead to a consensus among radiologists and treating cardiologists.

Keywords: Coronary Heart Disease; Pulmonary Hypertension; Heart Failure; Normal LV Ejection Fraction; Myocardial Viability; MRI; SPECT Synchronized With ECG; Nitroglycerin Test

Introduction

The use of multimodal methods, each based on different physical, biological and technical effects, requires specialized knowledge. Features of performing and interpreting the results of myocardial imaging, for example, gated SPECT, where images of metabolites of functioning cardiomyocytes are obtained, MRI using the magnetic resonance effect, together with traditional ECG and ECHO can vary significantly.

In general, the sensitivity and specificity of MRI and SPECT in the diagnosis of focal cardiosclerosis are quite close. But, most authors prefer MRI due to the better resolution of this method. If we evaluate the myocardium that remains viable, then discrepancies may arise in the area of non-transmural changes. In these cases, gated SPECT allows us to see what may appear non-viable on MRI.

Among tests assessing viable myocardium in patients with hypertension, especially pulmonary hypertension, not all will be able to reach the required threshold due to hypertension itself. Therefore, the choice of an effective test is important in each specific case.

Additional information about the state of the proximal coronary bed, obtained using coronary angiography, and visualization of the pulmonary circulation system, for example, using lung scintigraphy, to understand the mechanisms of pulmonary hypertension detected through a Swan Ganz catheter will help resolve the contradiction when making a diagnosis.

Heart failure itself with reduced LVEF remains an urgent problem in practical cardiology. But when clinical heart failure occurs with preserved LVEF, additional questions arise, both regarding the assessment of pathogenesis and treatment tactics.

Therefore, collective decision-making between radiologists and attending physicians becomes a necessity. The presented case, in our opinion, demonstrates these problems.

Case Report

A 65-year-old patient was in the cardiology department from 04 10 20 .. to 05 12 20 .. with a diagnosis of CAD, postinfarction cardiosclerosis (PICS) (right ventricular myocardial in-

farction (RV MI) of unknown duration, myocardial infarction of unknown duration, repeated non-Q- forming myocardial infarction of the anterior wall of the left ventricle 2 years ago). Percutaneous Coronary Intervention (PCI) and stenting of the right coronary artery (RCA), diagonal branch (DV) and anterior interventricular branch (ALA) of the left coronary artery (LCA), 2 years ago. PCI and stenting of the RCA and PIB of the LCA 1 year ago. Atherosclerosis of the aorta, coronary, cerebral arteries. Circulatory failure C-IV NYHA stage. Right-sided hydrothorax, hydropericardium, high pulmonary hypertension. Chronic hypoxemia.

Complaints on examination: shortness of breath at rest, severe general weakness, swelling of the scrotum and penis, difficulty urinating.

From the anamnesis: suffering from angina pectoris for 5 years. At the same time, the ECG for the first time revealed cicatricial changes, regarded as a transferred MI of unknown duration. Three years ago, he suffered a repeated Q forming myocardial infarction of the anterior wall of the left ventricle. Then coronary angiography (CAG) revealed: LAD stenosis in the proximal segment 95%, DV 90%, OB - occlusion, RCA stenosis in the proximal segment 90%, in the distal segment 95%. RCA, DV, LAD stenting was performed 2 years ago. In exercise tests, exercise tolerance was moderate, there were no ischemic changes. RCA stenting was performed 1 year later. Worsening of present condition within two weeks.

CONSILIUM (extract): at present, the severity of the patient's condition is due to significant pulmonary hypertension (mean PAP 110 - 115 mm tr st). Significant pulmonary hypertension was confirmed by catheterization of the pulmonary artery with a Swan-Ganz catheter, and values of 86 mm Hg were obtained.

According to the determination of arterial blood gases, hypoxemia was revealed (P O₂ = 48.2 mm Hg, norm 84 - 100 mm Hg) hypocapnia (P CO₂ = 28.0 mm Hg, norm = 35 - 45 mm Hg) compensated alkalosis pH=7.486.

At the control X-ray data for bilateral pneumothorax is not received. At the same time, significant pulmonary hypertension persists. D-shaped right ventricle, expansion of the right parts of the heart.

Currently, the genesis of significant pulmonary hypertension is not clear. Based on CT scan of the chest and lung scintigra-

phy, thromboembolic genesis was excluded. There are no data for systemic disease. Disseminated lung disease was excluded.

After therapy with diuretics, nitrates, anticoagulants, there is

a regression of heart failure in a large circle. Swelling of the scrotum and lower extremities are gone. After therapeutic treatment, the patient was discharged with a diagnosis of «pulmonary hypertension of unknown etiology».

Research Results

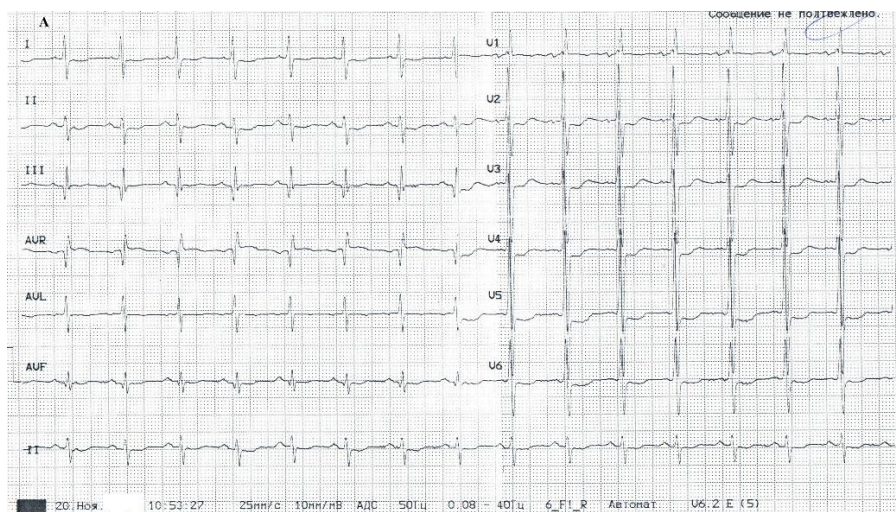


Figure A

ECG at admission: sinus rhythm, heart rate 88 min, Right Bundle Leg Block, scars of the lower wall without acute focal changes. (Figure A)

Echocardiography: upon admission, aorta 3.6 cm, LA 3.8 cm, RP 5.1x6.5 cm, RV 4.7 cm, Septum 1.7 - 2.0 cm, posterior wall of the left ventricle 1.6-1.7 cm, EDD LV 4.2 cm, ESD LV 2.7 cm, EF (Teicholz) 66%, EF (Simpson) 54%. Aortic valve reg. 0-1, Mitral valve reg. 2.0. Diastolic dysfunction Type 1, tricuspid valve reg 2 st., mean PAP= 95-100 mm Hg, LA valve - normal, diastolic PAP 40-45 mm Hg, LA is not dilated.

Chest CT: no conclusive evidence for TODAY

Lung scintigraphy: Convincing data for pulmonary embolism were not revealed.

MRI of the heart at admission (Figure B): Zone of fibrotic changes in the lateral and inferolateral walls of the left ventricle. Expansion of the cavity of the pancreas. There is an accumulation of contrast agent in the lower wall of the pancreas. Fluid contents in the pericardial cavity. Significant amount of fluid in the right pleural cavity.

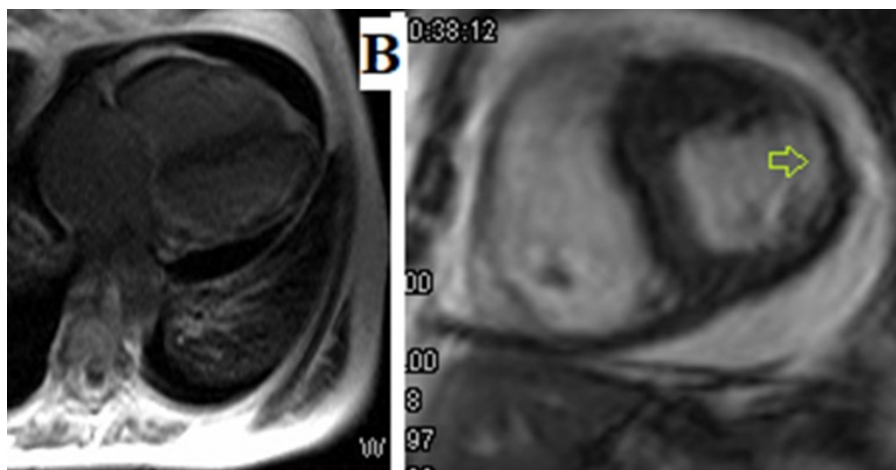


Figure B

Gated SPECT(Figure C): The myocardium of the non-en- larged LV is visualized with a significant subendocardial de- crease in perfusion of the entire lateral wall.

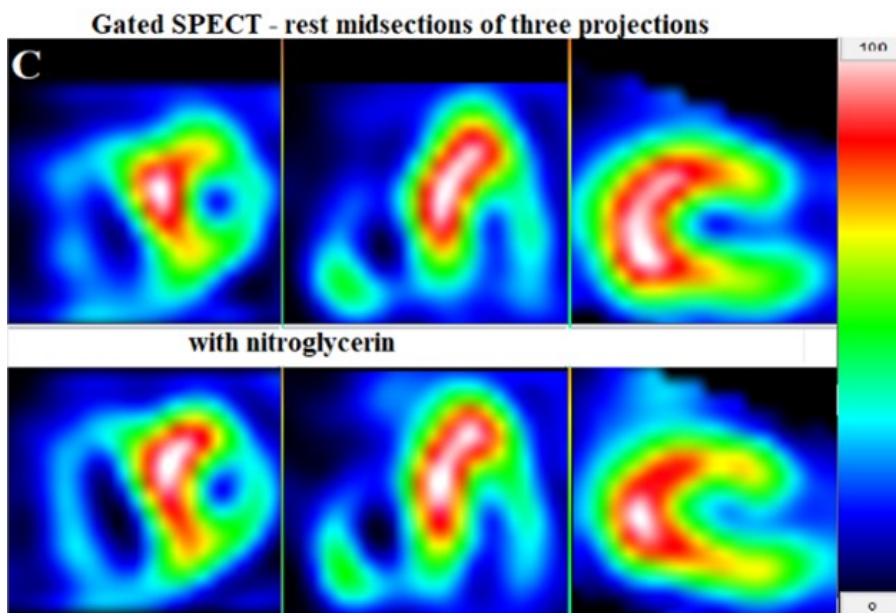


Figure C

Gated SPECT (Figure D): Moderate hypokinesia of the poste- rior septal LV. Profound decrease in all parameters of early LV filling. Extensive area of pathological asynchrony along the anterior wall of the left ventricle. LV EF = 60% (normal). In response to taking sublingual nitroglycerin, there was a ten-

dency to an increase in EDV within the normal range, aggra- vation of early filling disorders (Figure E), improvement in the function of the basal sections of the lateral wall, the occur- rence of hypokinesia of the medial sections of the lateral wall (pool of the LCA) (Figure D). LV EF=64%.

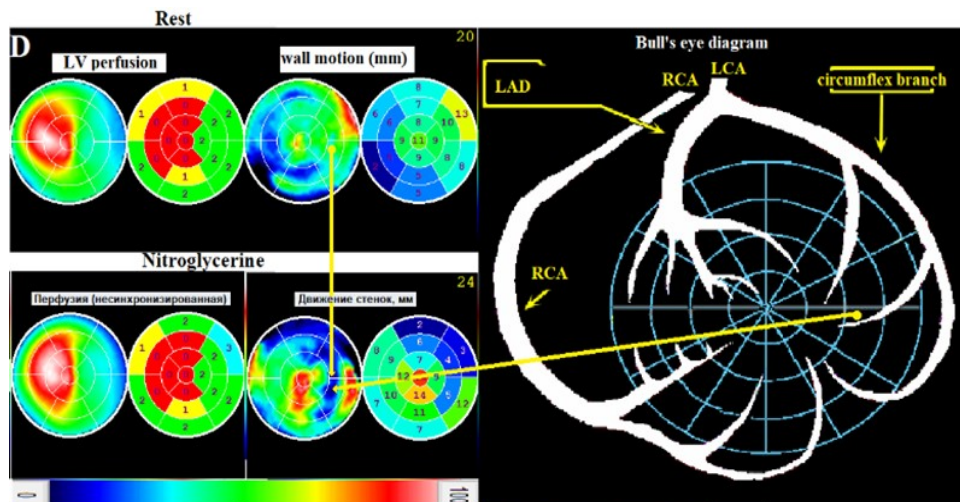


Figure D

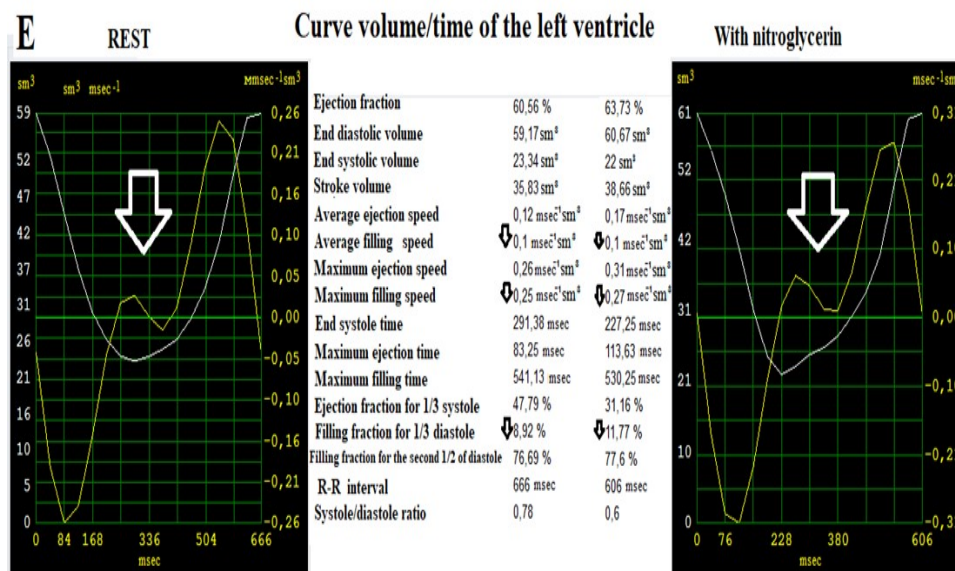


Figure E

Gated SPECT Conclusion: there were no signs of focal damage to the free wall of the pancreas. Distinct deep ischemia of the lateral wall of the left ventricle. Indications for coronary angiography.

Coronary angiography: The right type of coronary circulation. LCA trunk without stenosis. LAD in the proximal segment is the shadow of a previously implanted stent with restenosis of 20-25%, diffuse irregularities up to 45-50% in the middle segment. OA - total chronic occlusion in the middle segment with bridge-like collaterals. A large IV stent is traversable without signs of restenosis. RCA - contour irregularities up to 35-40%. Right ventricular branch at the mouth tubular eccentric stenosis 80%.

For Discussion

Clinical manifestations of heart failure against the background of severe pulmonary hypertension required an explanation of its etiology and pathogenesis.

The absence of any pathological changes in the lungs on x-ray, CT images, MRI and scintigraphy allowed us to exclude pulmonary causes of hypertension. In the absence of significant pathology of the heart valves, another cause of pulmonary hypertension could be a deep decrease in the parameters of early filling - diastolic dysfunction of the left ventricular myocardium itself.

Diastolic heart failure with normal LV ejection fraction is one of the characteristic manifestations of myocardial ischemia.

But there were no signs of ischemia on the resting ECG. Only signs of focal cardiosclerosis. Focal cardiosclerosis in the lateral, posterior, and diaphragmatic walls was confirmed by MRI images. This is probably why the attending physicians considered it inappropriate to perform PCI on an occluded LCA. No ischemia means no ischemic heart failure.

Focal changes in the myocardium of the same localization were also confirmed by isotope study, but they did not look transmural. Moreover, as an improvement in the function of the basal sections of the lateral wall, the occurrence of hypokinesis of its medial sections was noted, which indicated the presence of a viable myocardium here.

Comparing the informativeness of images of viable myocardium MRI and g-SPECT at rest, both of them provide a very close and accurate assessment of transmural foci of cardiosclerosis. When the thickness of the living myocardium remaining in the wall is compared with the thickness of the scar in it, discrepancies may arise, and MRI images, which perfectly determine the foci of cardiosclerosis, may not fully show the remaining myocardium and viability tests are necessary.

Here it is important to choose the right test that can be most effective in a particular clinical situation to answer the question of viability and myocardial ischemia. The presence of focal cardiosclerosis in our patient already made the electrocardiographic assessment of myocardial ischemia at rest difficult. The presence of high pulmonary hypertension made it doubtful whether a true threshold load could be achieved with an appropriate test. Therefore, in the current clinical situ-

ation, the test with nitroglycerin looks preferable.

In terms of today's clinical guidelines, it may seem that the nitroglycerin test is not standardized. But, if we turn to the original source, it turns out that Rahimtola also used nitroglycerin to prove the viability of the myocardium [1]. Then in 2003, clinical guidelines [2] proposed the use of nitroglycerin for the same purpose in radionuclide ventriculography. Some authors began to use sublingual nitroglycerin during g-SPECT as a pharmacological test in patients with coronary artery disease to assess myocardial viability [3].

It is important that in the clinical guidelines for myocardial revascularization in the section on the diagnosis of coronary artery disease for isotope imaging of the myocardium, results are cited, which were obtained using only myocardial perfusion indicators. The role of function estimation here was given exclusively to non-isotope methods. And only in the recommendations for the treatment of heart failure there is a desire to assess myocardial function by the method of perfusion SPECT synchronized with ECG (gated SPECT). This variant of SPECT allows you to get an image not only of perfusion, but also of myocardial function (parametric images), which has been shown in clinical guidelines for heart failure [4].

Parametric ECG-synchronized SPECT images are known to be particularly sensitive to focal changes in myocardial function such as motion, systolic thickening, and intraventricular asynchrony. However, the details of interpreting changes in myocardial function in such images may be familiar only to an experienced physician specializing in nuclear cardiology.

On the other hand, the standards in the detection of myocardial ischemia and / or its viability by various methods, starting with ECG and ECHO cardiography, including modern methods of direct imaging, such as isotope and MRI, cannot take into account all the disadvantages and advantages of each method in specific diagnostic situations and therefore exist only in the form of recommendations [5].

Moreover, the very concept of "viable myocardium" implies a myocardium that does not function at rest due to a lack of blood supply. That is, the myocardium, which is in a state of

ischemia. Therefore, the results of myocardial scintigraphy with a nitroglycerin test should be interpreted as the detection of a viable myocardium in a state of ischemia. In this case, the mechanism of heart failure was diastolic dysfunction as a result of ischemia of the viable LV lateral wall myocardium, and the solution suggests itself. However, after therapeutic treatment, the patient was discharged with a diagnosis of pulmonary hypertension of unknown etiology.

The medical press has already raised the issue of underestimating the importance of radioisotope methods in the diagnosis of viable myocardium [6]. The authors emphasized that clinical decisions should be based on data obtained by imaging ^{99m}Tc supplemented with nitrates [7]. Moreover, when comparing the prognosis and results of treatment of 89 patients with ischemic heart failure due to CAD using nitrate-stimulated SPECT with ^{99m}Tc-tetrofosmin and ¹⁸F-FDG-PET, we did not find a significant difference in survival in the viable myocardium group and in the nonviable myocardial group, visualized using SPECT or PET [8].

Instead of a conclusion

The case cited by us makes us think that several problems converged in it.

1 - HF in patients with preserved LV EF is still more rare than HF with reduced LV EF and therefore requires a detailed assessment of diastolic dysfunction (DD). Most often, the assessment of DD is performed during an ultrasound examination of the heart, but in our case, such a detailed assessment of DD was not carried out. Perhaps this is due to the fact that not everyone and not always understands the difference between DD and diastolic heart failure (DSF).

2 - The presence of viable (that is, ischemic, but not revascularized myocardium) is one of the important causes of DD. And therefore, it can be the cause of DSN. In this case, underestimation of the results of radioisotope methods, and even with the use of "non-standard tests" with nitroglycerin, can lead to an increase in the number of diagnoses with the words "of unknown etiology".

References

1. John HM, Mark TH, J Rosch, Frank EK, SH Rahimtoola MB (1975) Improvement in Left Ventricular Wall Motion Following Nitroglycerin, *Circulation*, 51.
2. ACC/AHA/ASNC (2003) Guidelines for the Clinical Use of Cardiac Radionuclide Imaging—Executive Summary, 108: 1404-18.
3. Gianni Bisi, Roberto SciagrÀ, Giovanni M Santoro, Francesca Zeraushek and Pier Filippo Fazzini (1994) Sublingual Isosorbide Dinitrate to Improve Technetium-99m-Teboroxime Perfusion Defect Reversibility, *J NuclMed*, 35: 1274-8.
4. ACCF/AHA (2013) Guideline for the Management of Heart Failure, *Circulation*, 128:e240-e327.
5. Gemma Cuberas-Borrós, Victor Pineda, Santiago Aguadé-Bruix, Guillermo Romero-Farina, M Nazarena Pizzi et al. (2013) Gated-SPECT myocardial perfusion imaging as a complementary technique to magnetic resonance imaging in chronic myocardial infarction patients, *Rev Esp Cardiol*, 66: 721-7.
6. Ilias Mylonas, Rob SB Beanlands (2011) “Radionuclide Imaging of Viable Myocardium: Is it Underutilized?” *Curr Cardiovasc Imaging Rep*, 4: 251–61.
7. Yang MF, Keng F, He ZX (2009) Nitrate-augmented myocardial perfusion imaging for assessment of myocardial viability: recent advances. *Nucl Med Commun*, 30: 415–9.
8. Sorrentino AR, Acampa W, Petretta M, Mainolfi C, Salvatore M, Cuocolo A (2007) Comparison of the prognostic value of SPECT after nitrate administration and metabolic imaging by PET in patients with ischaemic left ventricular dysfunction. *Eur J Nucl Med Mol Imaging*. 34: 558–62.

SMP Family Medicine
and Primary Care

SMP Cardiology and
Cardiovascular Medicine

SMP Human Nutrition
and Dietetics

SMP Pediatrics and
Child Health



SciMed Press
Publisher

SMP Journal of
Cancer Research

SMP Biotechnology and
Bioengineering

SMP Nanotechnology
and Nanomedicine

SMP Chemical
Engineering Science