

SMP Clinical Case Reports

A Rare Case of Giant Gastric GIST with Cystic Appearance Successfully Treated by Upfront Conservative Resection and Adjuvant Treatment: Case Report

Polistina FA^{*1}, Macchi L² and Frego M¹

¹Department of General and Oncologic Surgery, Padua sud Hospital, Monselice, Italy. via Albere 32, 35043 Monselice. Italy

²Padua University School of Surgery, Via Giustiniani 2, Padua, Italy

Publication Dates

Received date: January 08, 2022

Accepted date: February 08, 2022

Published date: February 10, 2022

* Corresponding Author

Polistina FA, Department of General and Oncologic Surgery, Padua sud Hospital, Monselice, Italy. via Albere 32, 35043 Monselice, Italy, Tel: +39 429 715884, E-mail: francescopolistina@hotmail.it

Citation

Polistina FA, Macchi L, Frego M (2022) A Rare Case of Giant Gastric GIST with Cystic Appearance Successfully Treated by Upfront Conservative Resection and Adjuvant Treatment: Case Report. SMP Clin Case Rep 1: 1-9

Abstract

Background: Gastrointestinal stromal tumors (GISTs) are uncommon mesenchymal neoplasms originating from interstitial cells of Cajal and characterized by cKIT overexpression. They can grow in virtually all segments of the digestive system and are most often asymptomatic. Most frequent site of appearance is the stomach where they may reach a very big size before getting diagnosed. GISTs are considered potentially malignant neoplasm and complete surgical resection is gold standard of their current treatment.

Case presentation: We present a case of giant gastric GIST (35x28x15cm) in a 76-year-old man who underwent radical resection by laparotomic gastric wedge resection. After the operation the patient underwent a six months Imatinib course and at the 5 years follow up, no recurrence occurred. We added a review of the recent literature about management of Giant GISTs.

Conclusion: Complete tumor resection with negative margins is the mainstay of treatment for resectable GISTs. This could be achieved via wedge resection over a more aggressive surgical approach also for Giant GIST. In case of unresectable GISTs imatinib therapy is the main treatment.

Keywords: GISTs; Gastric Neoplasms; Sparing Surgery

Introduction

Gastrointestinal stromal tumors (GISTs) are rare mesenchymal neoplasms, they account for 1-3% of all gastrointestinal tumors [1]. GISTs can occur in any portion of the alimentary tract but are most often located in the stomach (40 to 60%) and jejunum/proximal ileus (25 to 30%) [2].

Their pathologic origin comes from the interstitial cells of Cajal and their genetic pattern is characterized by the overexpression of the tyrosine kinase KIT (CD 117) that causes the activation of the oncogenic signaling pathway [3] [4]. Therefore, CD117 mutation is useful in the differential diagnosis between GISTs and other mesenchymal tumors of gastrointestinal tract like leiomyomas, leiomyosarcomas or others that doesn't present this mutation usually [5].

GISTs can occur predominantly in the middle-older ages (median age 64 years) without difference in males and females incidence [6]. Clinical presentation is often nonspecific; therefore early diagnosis is generally difficult.

In most cases, they are small and indolent and are discovered incidentally during endoscopic or radiologic exams for other reasons. Especially small GISTs can grow asymptomatic for long time, due to this their real prevalence is still unknown. When symptoms appear, most patients present variable clinical presentation, which mainly depends on the size and location of the tumor. Median tumor size at presentation in symptomatic patients is of about 5cm, although these tumors may grow much greater (30 cm and more) and the clinical course is considered potentially malignant.

Here we report on a case of giant gastric GIST (35x28x15cm) in a 76-year-old man who underwent complete surgical wedge gastric resection and a review of recent literature about giant GISTs (Table.1). Furthermore, we performed an extensive research on online scientific libraries retrieving all the papers reporting on "giant GISTs". Results of the search were compared to our findings and discussed below.

Case report

A 76-years-old man, with a medical history of essential hypertension well controlled by calcium antagonists oral

administration, came to our clinic referring abdominal discomfort associated with early satiety and mild weight loss reported over the last three months (about 8 Kg/3 months).

Furtherly, he referred of a concomitant progressive abdominal distension with no associated signs of hepatopathy or cardiac failure. On physical examination the abdomen was markedly distended by a voluminous, painless and firm palpable mass in left hypochondrium. Laboratory tests including neoplastic serum markers were unremarkable.

An abdominal contrast enhanced CT-scan showed a huge, partially cystic, mass measuring 35x28x15 cm, arising from anterior gastric wall and fundus and occupying almost entire abdominal cavity with neither radiologic signs of direct infiltration to the adjacent organs nor nodal enlargement or distant metastases (Figure 1). An Upper GI endoscopy pointed out the presence of a marked "ab extrinsic" compression on the gastric anterior wall and greater curvature without any mucosal lesion. Random gastric mucosal biopsies were negative. The patient gave complete informed consent to either treatment or use of anonymous data for scientific purposes.

Due to the increasing symptoms and the suspicion of mesenchymal neoplasm we proposed explorative laparotomy that the patient accepted. After a complete and irrelevant preoperative screening, the patient underwent the procedure that confirmed the presence of a bulky mass arising from the anterior gastric wall and fundus causing a remarkable dislocation of the whole intestinal mass. Careful blunt dissection allowed a complete separation of the mass from other abdominal viscera following macroscopically free surgical planes (Figures 2 and 3). An intraoperative frozen section of the mass wall resulted as non-diagnostic ("connective tissue rich in plasma cells"). Moreover, a single 3 mm firm nodule retrieved in the gastrocolonic ligament was excised. No signs of other macroscopic dissemination were found at complete abdominal examination and intraoperative liver echography. Therefore, the decision of a tissue sparing procedure was made and the mass was resected by a stapled wedge resection of the greater curve of the stomach (Figure 4).

The postoperative course was uneventful, and the patient was discharged fit and well on postoperative day seven.

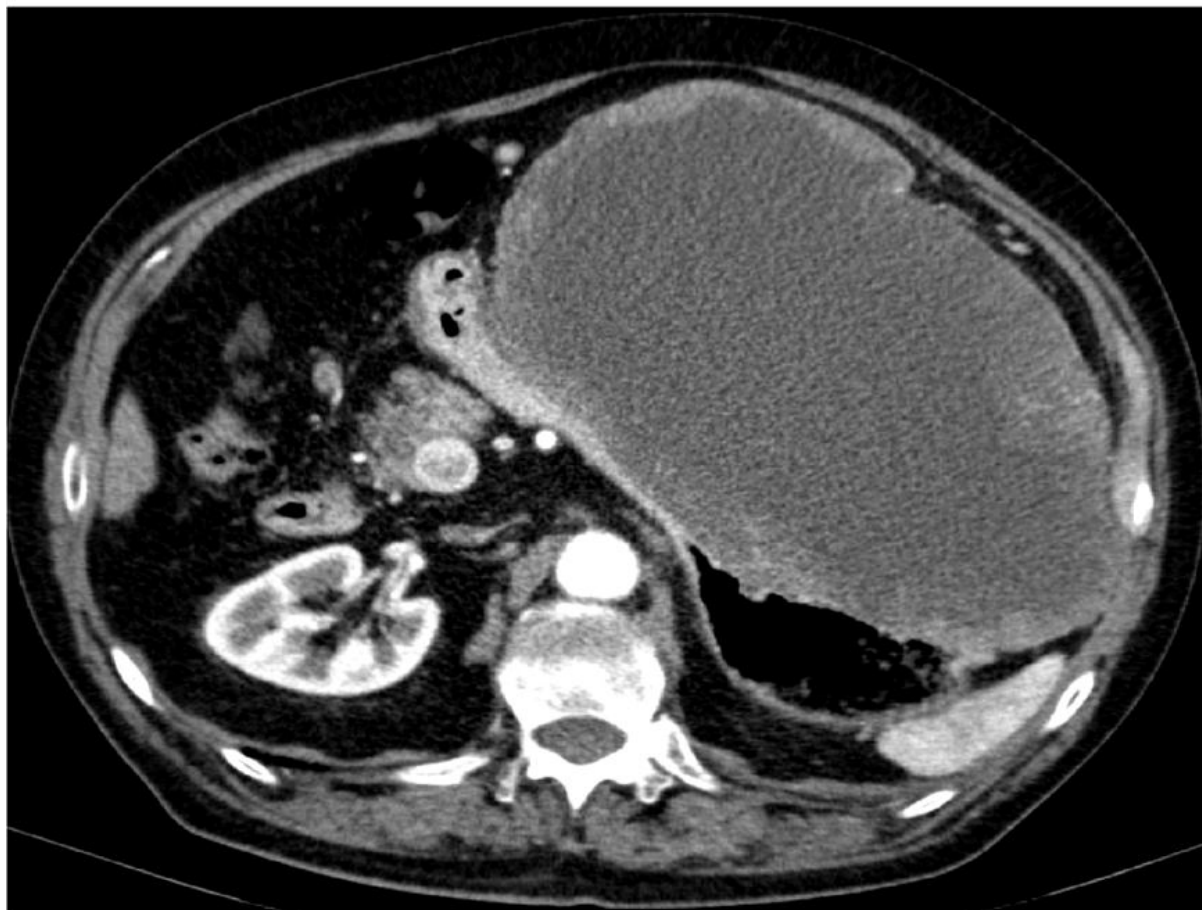

Figure 1: TC appearance of the mass

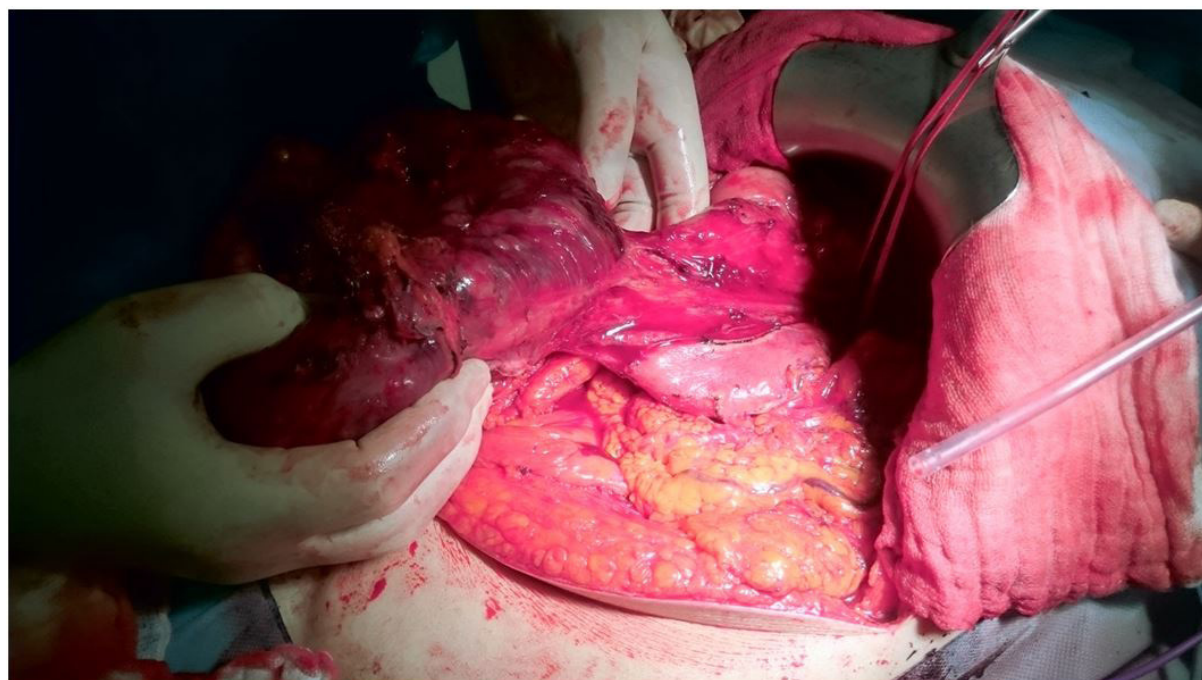


Figure 2: Intraoperative view after freeing the mass: to the origin from the gastric body

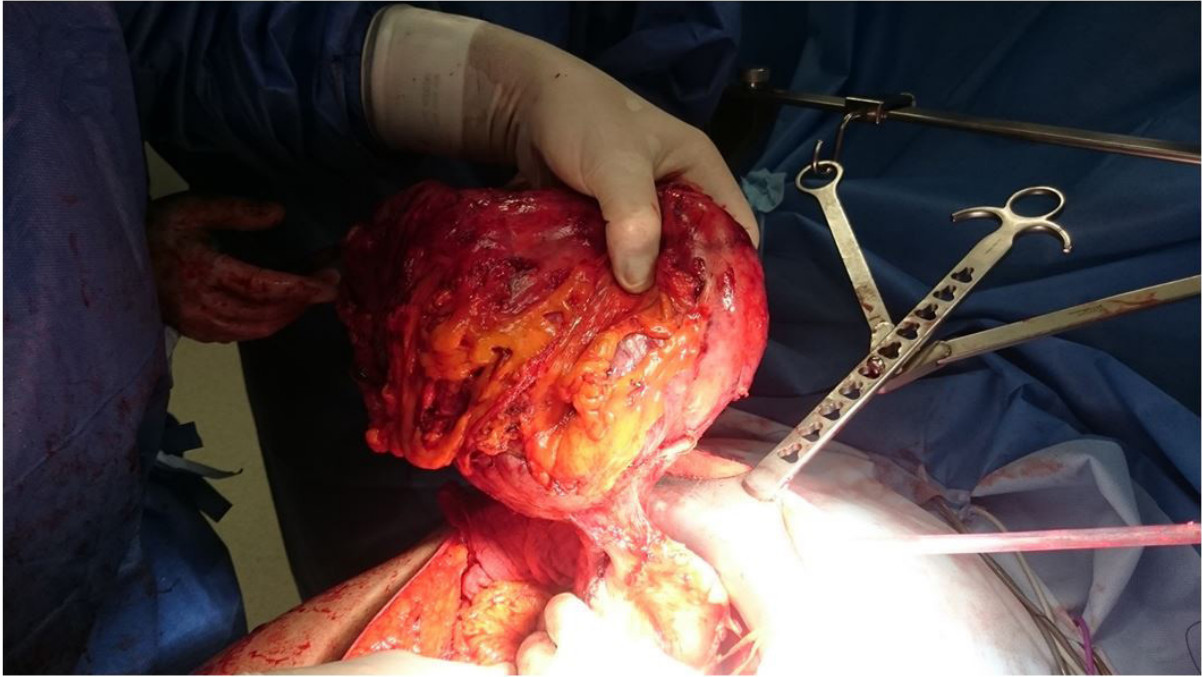


Figure 3: The mass is completely freed from attachments

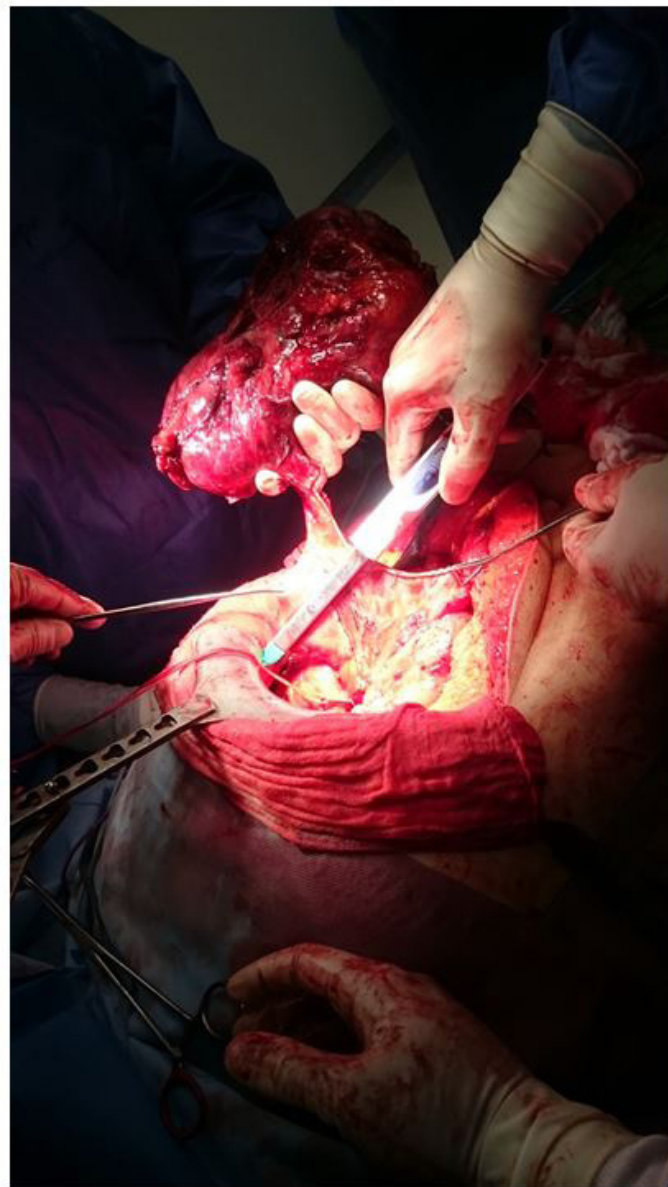


Figure 4: GIA wedge resection of the gastric wall removing the mass

The pathological examination showed a "Gastrointestinal Stromal Tumor with high grade neural and muscular differentiation, infiltrating the muscular layer without mucosal and submucosal involvement, with high mitotic index 5x50 HPF. Additionally. The gastro-colic ligament nodule was diagnosed as a GIST metastasis. Immunohistochemistry showed positivity for C-KIT, CD 34, Vimentin, NSE, Desmin, S-100, CK 8-18 weakly positive". According to size, location, mitotic count and the presence of distant spread, the tumor was categorized as high-risk GIST.

A staging, postoperative, ¹⁸F-FDG PET-CT was negative for any pathological captation and the patient started oral Imatinib therapy (Glivec[®], 400 mg/die for 36 months) with neither major nor minor side effects.

The follow-up continues, and the patient is alive and disease free at the 5-years follow-up.

The paper was approved by local BRB according to ethic guidelines. Non funding were required or obtained for the present study. All authors declare no conflict of interests.

Discussion

Despite are considered rare neoplasms, GISTs are the most frequent mesenchymal tumors affecting the gastrointestinal tract [7]. Clinical presentation is often nonspecific, therefore early diagnosis is generally difficult and their real prevalence is still unknown. Some patients are completely asymptomatic, with the tumor detected incidentally by imaging studies like abdominal CT, MRI or upper GI endoscopy performed for other reasons, while others present non-specific symptoms like dyspepsia, abdominal pain, gastrointestinal bleeding, palpable mass and compression signs related to the size of the tumor [8]. Laboratory findings are most often normal as generally are serum tumor markers.

Contrast-enhanced CT is the method of choice to study an abdominal mass suspected for GIST, to evaluate its extent, location and the presence of metastases frequently detected in the liver and peritoneum, while regional lymph nodes are rarely involved [9]. The presence of an extra-gastrointestinal GIST, located in the retroperitoneum, mesentery or omentum is exceptionally rare, we found only one case reported in our review [10].

During upper endoscopic study GIST usually appears as a submucosal mass bulging into the gastric lumen with smooth margins and a normal overlying mucosa. Endoscopic sensibility is furtherly enhanced by endoscopic ultrasonography that allows to obtain guided biopsy to confirm the diagnosis [11]. We did

not perform neither EUS nor endoscopic biopsy because the mass was huge and radically resectable on CT and the patient presented with major symptoms.

According to current guidelines, biopsies are generally not recommended for resectable lesions highly suspected for GIST in patients fit for surgical intervention. However, if target therapy is considered prior to surgery, like in metastatic or non resectable GISTs, a histological confirmation is encouraged despite the risk of perforation or non-diagnostic sampling [12].

Surgical and/or endoscopic resection is the first choice for technically resectable GISTs without metastasis [13]. Mini-invasive approaches, either endoscopic or laparoscopic, according to tumor position and equippe's skills are nowadays considered as the gold standard of GISTs treatment, especially for GISTs smaller than 5 cm [14]. For larger GISTs the role of laparoscopy is still under debate for feasibility and safety. Most technical problems, in this particular setting, are the lack of intra-abdominal space due to the presence of the mass, the frequent presence of a tumoral pseudo-capsule that renders really difficult the tumor's dissection with laparoscopic instruments and the risk of rupturing the tumor's capsule with subsequent tumor seeding within abdominal cavity. In this case we decided for the upfront laparotomic approach due to the huge tumor's dimension with the related risk of intraoperative rupture during laparoscopic maneuvers done in very limited spaces. In our review only one patient underwent laparoscopic total gastrectomy [15] and he beared a relatively small GIST measuring 13 cm (the smallest reported), while the greatest part of authors choose a surgical approach similar to ours. On the extent of resection, once again, there are no clear indications. Many classifications (NIH, AFIP, and modified NIH, TNM) have been developed to stratify the risk of malignancy and recurrence but to date none of them is considered to be completely exhaustive [16]. Despite this, GIST size, location, mitotic rate and rupture are considered the main prognostic factors. The presence of metastases does not contraindicate surgical removal of the primary tumor, while neoadjuvant imatinib should be considered for those large gastric or rectal primaries. Wide resection margins have not been associated with improved oncologic outcomes and routine lymphadenectomies are unnecessary as these tumors rarely spread to regional lymph nodes [17], in our case we were able to perform a minimal surgical resection on the gastric wall despite a more aggressive approach like total gastrectomy achieving negative margins and preserving gastrointestinal anatomy.

Extensive resections as total or subtotal gastrectomy may be deemed necessary according to tumor characteristics of local

invasion, site of origin or team's choice. Reviewing published data, we retrieved 11 giant GISTs reported. Most of them were gastric (9/11), one was jejunal and one was retroperitoneal. Maximum diameter ranged from 13 to 39 cm. Complete data on surgical treatment are available for 9 of them; in two cases a total gastrectomy was performed while others have been treated by segmental or subsegmental resection on demand. We feel that there is no clear indication to extensive demolition since the local recurrence rate of GISTs is reported to be very low and no impact has been clearly identified of the extension of resection on patient's survival. Moreover, it is widely well known that extensive demolitions carry a significantly higher risk for surgical complications as well as for postoperative medical morbidity. Therefore, since there was no evidence of any macroscopic residual disease, the wedge resection appeared as the most appropriated treatment for that condition.

Histopathological analyses of the specimen confirmed the diagnosis of giant GIST developed between the extramuscular and peritoneal surface of the anterior aspect of the greater curve of the stomach. Immunohistochemical study showed positivity for typical CD117, which distinguishes GIST from other mesenchymal tumors. The tumor also showed positive staining for S100 protein, a neurogenic marker that is secreted in the Auerbach neural plexus and interstitial Cajal cells, which shows the tumor's neural differentiation. Moreover, the high mitotic index and the presence of a distant (peritoneal) spread classified the tumor as high risk with a clear indication for adjuvant treatment. Moreover only one of the 8 patients for whom there are follow-up data, showed a relapse of the disease with an unreported DFS. Only factors that correlate with the recurrence seem to be the high mitotic index and the presence of extra-gastric spread at operation as is well known for all GISTs. Our case substantially confirms these data. To our knowledge, it is the second greatest reported gastric GIST showing biologic and histologic features similar to smaller ones and with a comparable outcome as for others giant GISTs reported.

Patients who undergo surgical resection should be monitored for recurrence with serial abdominal CT or PET-TC scans. ¹⁸F-FDG PET is not routinely used for initial diagnosis but represent the most useful imaging study to assess the response to tyrosine kinase therapy and was performed in our case for postoperative stadiation without evidence of residual disease before starting adjuvant therapy.

The introduction of adjuvant therapy with imatinib has dramatically changed the management of GISTs and should be considered as the standard treatment in all patients with

significant risk of recurrence following resection. DeMatteo et al. reported that adjuvant Imatinib therapy improves the recurrence free survival of primary GIST tumors, especially those over 10cm [18]. In reported cases six patients received adjuvant Imatinib, two patients received Imatinib in both neoadjuvant and adjuvant settings, one patient received neoadjuvant Imatinib only and in two cases there are no data enough to state if and which medical treatment patient have had. In no case there are reported data on the duration and dose of targeted therapy given. Our patient received the standard treatment of Imatinib 400 mg by mouth for 3 years showing a very good response and tolerance to treatment and no side effects.

Conclusions

Giant GISTs are rarely reported in literature and still represent a challenging issue. They don't differ from smaller GISTs in term of epidemiology, gastric location prevalence, treatment or survival but represent a challenge for their technical surgical management. Extensive resections are commonly considered the standard treatment to achieve negative margins especially for giant GIST. We suggest, as reported in our case report and according to similar reports from literature, that a conservative approach preserving gastrointestinal anatomy is oncological effective also for giant lesions in selected patients depending on tumor location.

References

- Rossi CR, Mocellin S, Mencarelli R, Foletto M, Pilati P et al. (2003) Gastrointestinal stromal tumors: from a surgical to a molecular approach. *Int J Cancer* 107: 171-6.
- Søreide K, Sandvik OM, Søreide JA, Giljaca V, Jureckova A, et al. (2016) Global epidemiology of gastrointestinal stromal tumours (GIST): A systematic review of population-based cohort studies. *Cancer Epidemiol* 40: 39-46.
- Hirota S, Isozaki K, Moriyama Y, Hashimoto K, Nishida T, et al. (1998) Gain-of-function mutations of c-kit in human gastrointestinal stromal tumors. *Science* 279: 577-80.
- Rubin BP, Singer S, Tsao C, Duensing A, Lux ML, et al. (2001) KIT activation is a ubiquitous feature of gastrointestinal stromal tumors. *Cancer Res* 61: 8118-21.
- Dow N, Giblen G, Sobin LH, Miettinen M (2006) Gastrointestinal stromal tumors: differential diagnosis. *Semin Diagn Pathol* 23: 111-9.
- Mazzola P, Spitale A, Banfi S, Mazzucchelli L, Frattini M, et al. (2008) Epidemiology and molecular biology of gastrointestinal stromal tumors (GISTs): a population-based study in the South of Switzerland, 1999-2005. *Histol Histopathol* 23: 1379-86.
- Miettinen M, Lasota J (2006) Gastrointestinal stromal tumors: review on morphology, molecular pathology, prognosis, and differential diagnosis. *Arch Pathol Lab Med* 130: 1466-78.
- Demetri GD, von Mehren M, Antonescu CR, DeMatteo RP, Ganjoo KN et al. (2010) NCCN Task Force report: update on the management of patients with gastrointestinal stromal tumors. *J Natl Compr Canc Netw* 8 Suppl 2: S1-41-4.
- Fletcher CD, Berman JJ, Corless C, Gorstein F, Lasota J, et al. (2002) Diagnosis of gastrointestinal stromal tumors: a consensus approach. *Int J Surg Pathol* 10: 81-9.
- Ashoor AA, Barefah G (2020) Unusual presentation of a large GIST in an extraintestinal site: a challenging diagnosis dilemma. *BMJ Case Rep* 13: e229839.
- Sepe PS, Moparty B, Pitman MB, Saltzman JR, Brugge WR (2009) EUS-guided FNA for the diagnosis of GI stromal cell tumors: sensitivity and cytologic yield. *Gastrointest Endosc* 70: 254-61.
- Nishida T, Kawai N, Yamaguchi S, Nishida Y (2013) Submucosal tumors: comprehensive guide for the diagnosis and therapy of gastrointestinal submucosal tumors. *Dig Endosc* 25: 479-89.
- Karakousis GC, Singer S, Zheng J, Gonen M, Coit D, et al. (2011) Laparoscopic versus open gastric resections for primary gastrointestinal stromal tumors (GISTs): a size-matched comparison. *Ann Surg Oncol* 18: 1599-605.
- Ortenzi M, Ghiselli R, Cardinali L, Guerrieri M (2017) Surgical treatment of gastric stromal tumors: laparoscopic versus open approach. *Ann Ital Chir* 88: S0003469X17026112.
- Kermansaravi M, Rokhgireh S, Darabi S, Pazouki A (2017) Laparoscopic total gastrectomy for a giant gastrointestinal stromal tumor (GIST) with acutemassive gastrointestinal bleeding: a case report. *Wideochir Inne Tech Maloinwazyjne* 12: 306-10.
- Khoo CY, Chai X, Quek R, Teo MCC, Goh BKP (2018) Systematic review of current prognostication systems for primary gastrointestinal stromal tumors. *Eur J Surg Oncol* 44: 388-94.
- Choi SM, Kim MC, Jung GJ, Kim HH, Kwon HC, et al. (2007) Laparoscopic wedge resection for gastric GIST: long-term follow-up results. *Eur J Surg Oncol* 33: 444-7.
- Dematteo RP, Ballman KV, Antonescu CR, Maki RG, Pisters PW, et al. (2009) Adjuvant imatinib mesylate after resection of localised, primary gastrointestinal stromal tumour: a randomised, double-blind, placebo-controlled trial. *Lancet* 373: 1097-104.
- Melo C, Canhoto C, Manata F, Bernardes A (2018) Surgical treatment of giant gist with acute gastrointestinal bleeding: Case report. *Int J Surg Case Rep* 53: 354-7.
- Ismael H, Ragoza Y, Cox S (2017) Using endoscopy to minimize the extent of resection in the management of giant GISTs of the stomach. *Int J Surg Case Rep* 36: 26-9.
- Matsuo K, Inoue M, Shirai Y, Kataoka T, Kagota S, et al. (2018) Giant GIST of the stomach: a successful case of safe resection with preoperative simulation using threedimensional CT angiography: Case report. *Medicine (Baltimore)* 97: e9945.

22. Wang L, Liu L, Liu Z, Tian Y, Lin Z (2017) Giant gastrointestinal stromal tumor with predominantly cystic changes: a case report and literature review. *World J Surg Oncol* 15: 220.
23. Fukuda S, Fujiwara Y, Wakasa T, Kitani K, Tsujie M, et al. (2017) Giant gastric gastrointestinal stromal tumor with severe peritoneal dissemination controlled by imatinib therapy following debulking surgery: a case report. *J Med Case Rep* 11: 33.
24. Navarrete A, Momblán D, Almenara R, Lacy A (2017) Giant Gastric Gastrointestinal Stromal Tumor (GIST). *J Gastrointest Surg* 21: 202-4.
25. Sun KK, Xu S, Chen J, Liu G, Shen X, et al. (2016) Atypical presentation of a gastric stromal tumor masquerading as a giant intraabdominal cyst: A case report. *Oncol Lett* 12: 3018-20.
26. Koyuncuer A, Gönlüşen L, Kutsal AV (2015) A rare case of giant gastrointestinal stromal tumor of the stomach involving the serosal surface. *Int J Surg Case Rep* 12: 90-4.

